

Using Dentition to Age Cattle

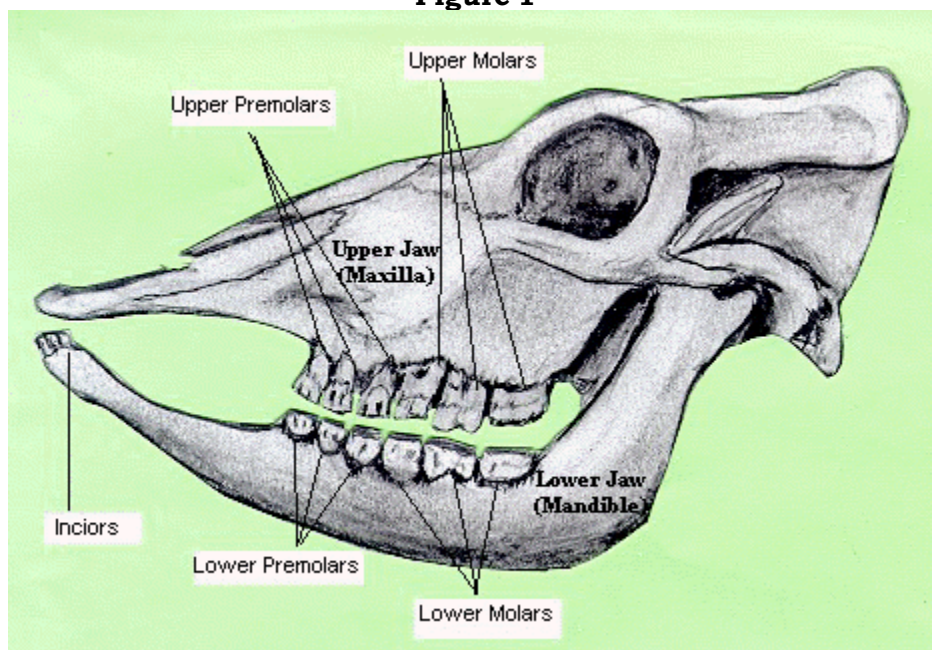
For many years, producers, veterinarians, and exhibitors (at cattle shows) have used cattle dentition to make general age determinations. Dentition will vary from herd-to-herd and animal-to-animal, because of the animal's genetics, their diet, and the varied geographical locations in which they are raised. **Despite individual differences, when the age of an animal is not known, examination of the teeth serves as the best and most practical method of age determination.** This document will serve as FSIS guidance for aging cattle.

In order to age cattle using dentition, some background information is necessary. This document will discuss and demonstrate: types of teeth and their location in bovine jaws, deciduous incisors versus permanent incisors, eruption times for deciduous and permanent teeth and using eruption times of permanent incisors to age cattle.

Tooth types and location

There are three types of teeth found in the bovine: incisors, premolars and molars. Incisor teeth are found in the rostral portion of the mouth, but they are absent from the upper jaw. The premolars and molars (known as cheek teeth) are found in the caudal part of the mouth and are present in the upper (maxilla) and lower (mandible) jaws. The following schematic (**Figure 1**) of the bovine skull, from an older animal (all permanent teeth* are present), demonstrates the location of the teeth.

Figure 1



***At birth, calves have deciduous (temporary, milk, baby) teeth. The deciduous teeth are lost as the animal ages and they are replaced by the permanent teeth.**

Deciduous (Temporary) Teeth

Calves have a total of 20 deciduous teeth. There are no deciduous molars and deciduous premolar 1 is not present. The dental formula for the deciduous teeth follows:

Deciduous teeth: $2(Di\ 0/4, Dc\ 0/0, Dp\ 3/3) = 20$ deciduous teeth

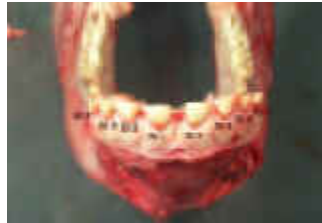The eruption of the deciduous teeth varies somewhat; about 75 percent of the well-bred calves have all incisors erupted at birth. Average periods of eruption of the deciduous teeth in cattle follow:

Table 1 – Eruption Times of Deciduous Teeth	
Teeth	Age at eruption
First Incisor (Di* 1)	Birth to 2 weeks of age.
Second Incisor (Di 2)	“
Third Incisor (Di 3)	“
Fourth Incisor (Di 4 or C)	“
First Cheek Tooth (Dp* 2)	Birth to a few days of age
Second Cheek Tooth (Dp 3)	“
Third Cheek Tooth (Dp 4)	“
* Di = deciduous incisor Dp = deciduous premolar	

In photograph 1, the rostral view of a mandible from a young bovine

demonstrates the location of the different deciduous incisors; they are identified – Di 1 through Di 4.

Photograph 1



Click on the photograph for an enlarged image.

Permanent Teeth

Deciduous teeth are replaced by permanent teeth as the animal ages. Premolar 1 is not present. The dental formula for the permanent teeth of cattle follows

Permanent teeth: $2(I\ 0/4, C\ 0/0, P\ 3/3, M\ 3/3) = 32$
permanent teeth

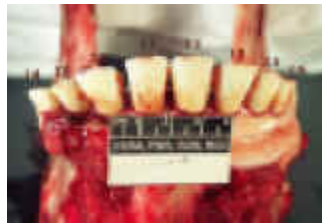Average periods of eruption of the permanent teeth in cattle are found in the following table:

Table 2 – Eruption Times of Permanent Teeth	
Teeth	Age at eruption
First Incisor (I* 1)	18 – 24 months
Second Incisor (I 2)	24 – 30 months
Third Incisor (I 3)	36 months
Fourth Incisor (I 4 or C)	42 – 48 months

First Cheek Tooth (P* 2)	24 – 30 months
Second Cheek Tooth (P 3)	18 – 30 months
Third Cheek Tooth (P 4)	30 – 36 months
Fifth Cheek Tooth (M 2)	12 – 18 months
Sixth Cheek Tooth (M 3)	24 – 30 months
* I = Incisor P = Premolar M = Molar	

The photograph (**Photograph 2**) below shows a mandible from a cow with all of her permanent incisors present. The incisors are identified – I 1 through I 4.

Photograph 2



Click on the photograph for an enlarged image.

Note:

In addition to the simple numerical designations for teeth, the following terms are commonly applied to the individual incisors: central (Di 1 or I 1), first intermediate or middle (Di 2 or I 2), second intermediate or lateral (Di 3 or I 3), and corner incisors (Di 4 or I 4). Canine teeth are absent in cattle, unless the fourth incisor (I 4), or corner incisor, is considered to be a canine tooth. If Di 4 or I 4 is considered to be a canine tooth, then the dental formulas change, slightly, to the following:

Deciduous formula: $2(Di\ 0/3, C\ 0/1, Dp\ 3/3) = 20$
teeth

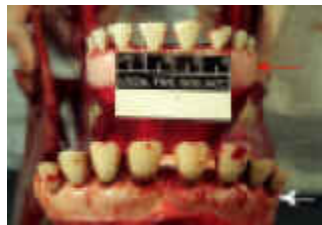Permanent formula: $2(I\ 0/3, C\ 0/1, P\ 3/3, M\ 3/3)$
= 32 teeth

A dental formula is an abbreviated statement of the number and types of teeth found on one side of the top and bottom jaw. Because the dentition is the same on both sides of the jaw, the formula lists only one side, and is enclosed in parentheses and multiplied by 2 to arrive at the total number of teeth. Numbers above the lines are for the teeth located in the upper jaw and those below the line are for the teeth in the lower jaw.

Deciduous (temporary) incisors versus permanent incisors

The deciduous incisors differ from the permanent incisors in being much smaller. The crowns (that part of the tooth that is covered with enamel) of the deciduous incisors are narrower than the permanent incisors and they diverge more from the base (at the gum line) of the tooth to the apex when compared to the permanent incisors. Photograph 3 compares the mandibles (lower jaws) from a young animal with deciduous incisors (red arrow) to an older animal with permanent incisors (white arrow). The difference in tooth size and shape and jaw width (and size) can be appreciated.

Photograph 3



[Click on the photograph for an enlarged image.](#)

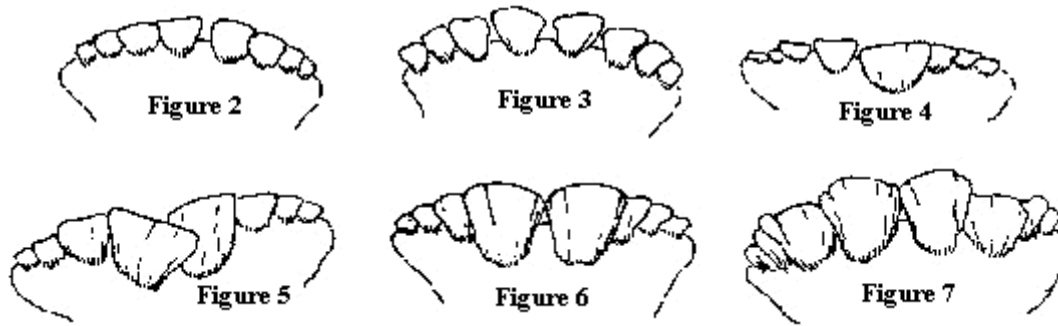
Using teeth to age cattle

Cattle dentition is generally used as an indicator of age when actual birthdates are not available. Eruption times and wear of the teeth are the major factors used to estimate bovine age. **This guidance document will base the aging of cattle on the eruption times for the permanent incisors.**

The **definition of eruption** is the emergence/penetration/piercing of the tooth/teeth through the gingiva (the gum line).

Eruption of teeth in cattle typically follows the pattern shown in the **Figures 2 - 7** below. The figures represent the incisor dentition from young animals through animals that are 30 months of age or older.

An animal 14 months of age would have a full set of deciduous incisors as shown in **Figure 2**. All four pairs of teeth are temporary and firmly in place. The teeth are short, broad and usually have a bright, ivory color. There is usually space between the Di 1 incisors. Other incisors may touch on the inside corner at the top of the tooth. As the animal ages, the deciduous teeth become loosely set in the jaw, especially the central 2 incisors. The teeth appear longer and narrower (**Figure 3**) than in younger animals and the teeth may or may not be touching at the upper corners; an animal with this dentition is approximately 15 – 18 months of age.

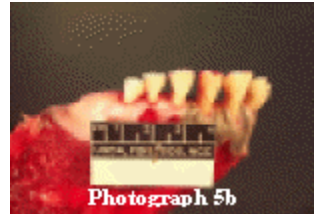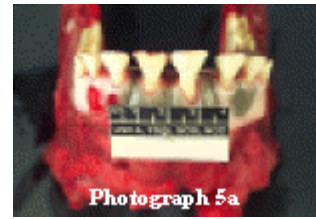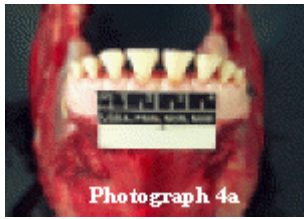


In **Figure 4**, a permanent central (I 1) incisor has erupted; temporary incisors may or may not be present when the permanent incisor erupts. The permanent incisors usually erupt at an angle (**Figure 5**) and straighten into a definite pattern with growth. In **Figure 5**, both central (I 1) incisors have erupted; they may or may not be in a straight line with the inside corners touching. The central incisors, in **Figure 6**, are in place, they have straightened and the inside corners are in line. Animals with eruption of one or more central incisors are considered to be 18 – 24 months of age. When one or both middle (I 2) incisors erupt the animal is considered to be 24 – 30 months of age (**Figure 7**).

The following sets of photographs will demonstrate the aging of cattle, based on dentition, from 15 months to greater than 42 months of age. These animals were aged using Table 1 and Table 2 above. The photographs will show a rostral view and at least one rostrolateral view of each set of teeth. (The following photographs are thumbnails, so please click on them to get the enlarged image).

Cattle 15 – 18 Months of Age

The following four photographs show a rostral (**Photograph 4a and 5a**) and rostrolateral (**Photograph 4b and 5b**) view of the dentition on the lower jaw. All deciduous incisors are evident. These temporary teeth are often loosely set in the jaw; especially the central incisors (Di 1). The animals are approximately 15 - 18 months old. In photographs 5a and 5b, the central incisors were very loose. Also, as described for Figure 2 above, the incisors are longer and narrower when compared to younger animals.



Click on the photograph for an enlarged image.

Cattle 18 - 24 Months of Age

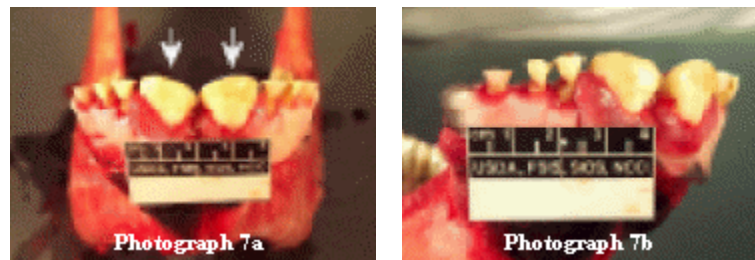
The eruption of the first central incisor (or incisors) indicates that the animal is in the age range of 18 - 24 months as indicated in Table 2 above. The Di 1 deciduous incisors may or may not be present when the central incisors erupt.

The following three photographs show the eruption of the central (I 1) permanent incisors; the deciduous incisors have been lost. One incisor (white arrow), in photograph 6a, has recently erupted while the other incisor (red arrow) has been exposed, due to the gingiva being artificially torn during processing; this incisor had not penetrated the gum line. Photograph 6c gives a better view of the erupted incisor (white arrow).



Click on the photograph for an enlarged image.

These photographs (7a and 7b) show that the central incisors (I 1) have erupted and are fully developed, but are not in wear. The eruption of the central incisors indicates that the animal is in the 18 - 24 month age range. White arrows identify the central incisors in photograph 7a.



Click on the photograph for an enlarged image.

Photographs 8a and 8b show that the central incisors have erupted. These incisors are fully developed. This animal is in the 18 - 24 month age range.



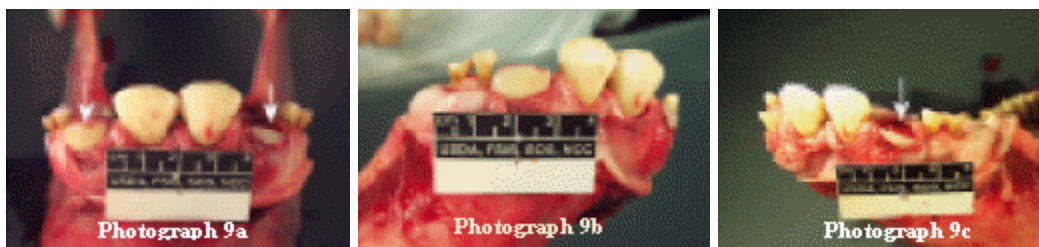
Click on the photograph for an enlarged image.

Cattle 24 – 30 Months of Age

Cattle that have the middle (I 2) incisor (or incisors) erupted are in the 24 – 30 month age range as indicated by Table 2 above.

However, FSIS, as written in FSIS Notice 5-04, is using a conservative approach and is determining that cattle with eruption of at least one of the second set of permanent incisors (I 2) is 30 months of age or older. FSIS would consider the animal in photographs 9a – 9c to be 30 months of age or older; the animal in photographs 10a and 10b is also considered to be 30 months of age or older.


These three photographs (9a – 9c) show the eruption of the middle (I 2) incisors. The white arrows in photograph 9a locate the I 2 incisors; the central (I 1) incisors (found between the I 2 incisors) have erupted and are fully developed. Photographs 9b and 9c are rostro- lateral views of the lower jaw. These photographs demonstrate the variation in eruption of the I 2 incisors. The I 2 incisor (white arrow) in photograph 9c has recently erupted.



Click on the photograph for an enlarged image.

In photographs 10a and 10b, the central (I 1) and middle (I 2) set of incisors have erupted.

The I 1 incisors are identified by the white arrows and I 2 incisors by the red arrows in photographs 10a and 10b.

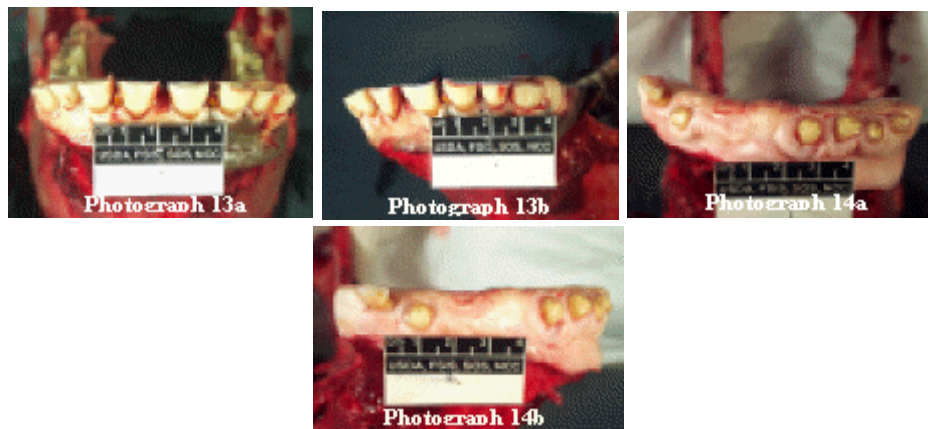
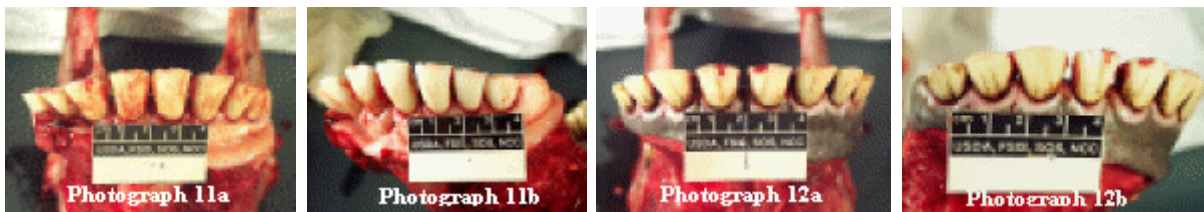


Click on the photograph for an enlarged image.

Cattle Greater Than 30 Months of Age

The eruption of the lateral (I 3 or second intermediate) incisor (or incisors) indicates that the animal has reached 36 months of age. The eruption of the corner (I 4) incisor (or incisors) indicates that the animal has reached at least 42 months of age. These ages are based upon permanent incisor eruption times found in Table 2 above.

The following 4 sets of photographs are representative of animals that are at least 42 months of age or older. These photographs (as you move from Photograph 11 through 14) also demonstrate that as cattle age the teeth are worn down. Photographs 14a and 14b demonstrate what happens after years of use; the teeth have worn down to what are called “peg teeth”.



Click on the photograph for an enlarged image.

References

1. Sisson, S and Grossman, J. D. *The Anatomy of Domestic Animals*. 4th edition, 1953. W. B. Saunders, Philadelphia .
2. Getty, R. *Sisson and Grossman's: The Anatomy of the Domestic Animals*. 5th edition, 1975. W. B. Saunders, Philadelphia .
3. <http://edis.ifas.ufl.edu/AN046>
4. Nickel, R, Schummer, A, Seiferle, E and W O Sack. *The Viscera of the Domestic Animals*. 1973, Springer-Verlag , New York .
5. <http://www.tnbeefcattleinitiative.org/shirtpocketinfosheets/sp11.pdf>
6. *The Stockman's Handbook*. 6th Edition by M. E. Ensminger, Copyright 1983 by Interstate Printers and Publishers.

**For further clarification or questions about this correlation material
please contact the Policy Development Division**